

Pre-Prosthetic Treatment with Invisalign

Dr. Ben Miraglia

November 2008 ATE call

invisalign

Dr. Ben Miraglia

- Graduate of State University of New York at Buffalo Dental School and Practices in Mount Kisco, NY
- Practice Focus includes Family Dental Practice, Full Mouth Reconstruction including Invisalign and Implants
- Has Treated 150 Invisalign Cases to date and has finished over 100
- Active member of ADA, AGD and New York 9th District Dental Society
- Recipient of 2006 Westchester County Community Service Award for providing dentistry to developmentally disabled residents
- Is featured in the recently released GP Case Gallery and is a regular Study Club regional speaker for Align Technology
- Main Stage Speaker at the Invisalign 2007 Annual National Summit Meeting in Las Vegas, NV
- Member of Aligntech Institute Faculty

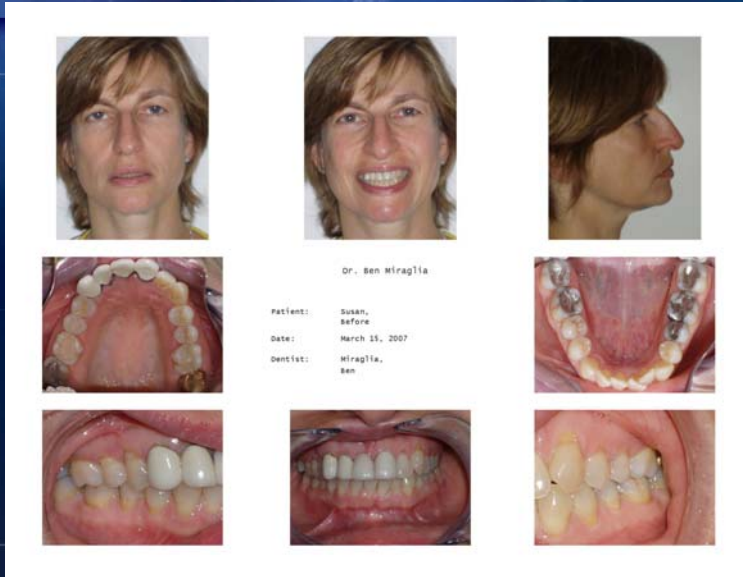The person who
says it cannot be
done should not
interrupt the person
doing it.

-Confucius

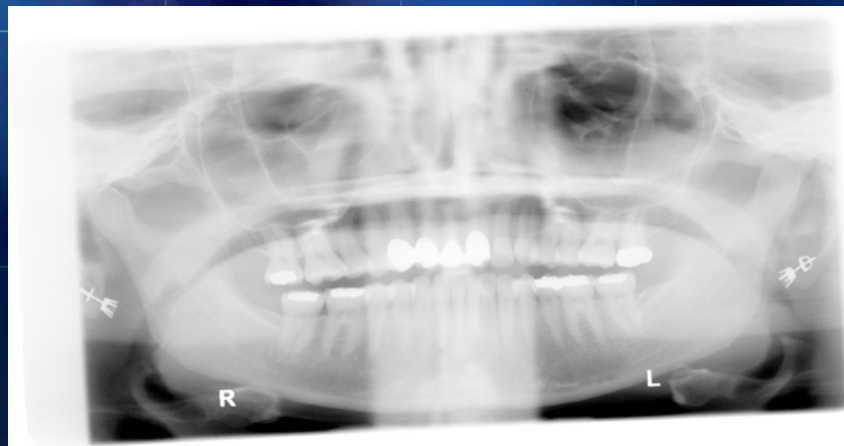Agenda

- Introduction
- Pre-Prosthetic Interdisciplinary Care
- 3 Clinical Case Presentations

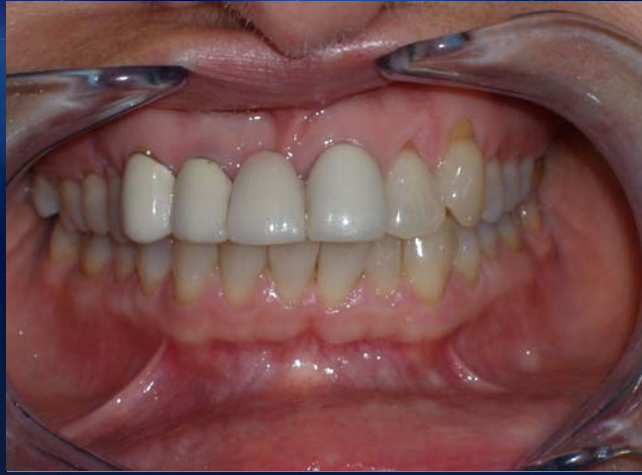Susan - 48 Years Old 15 Months Treatment Time



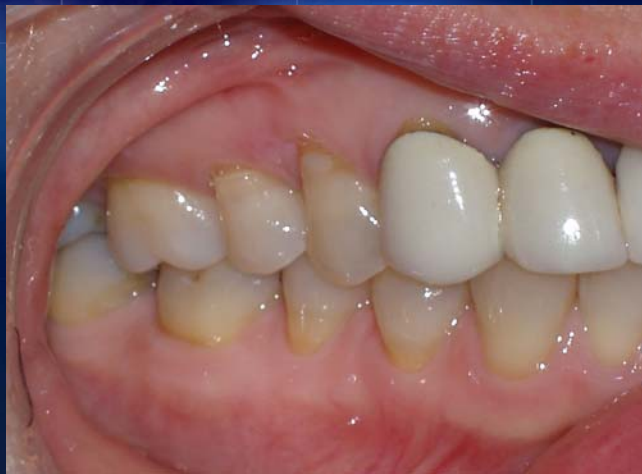Susan's X-Ray



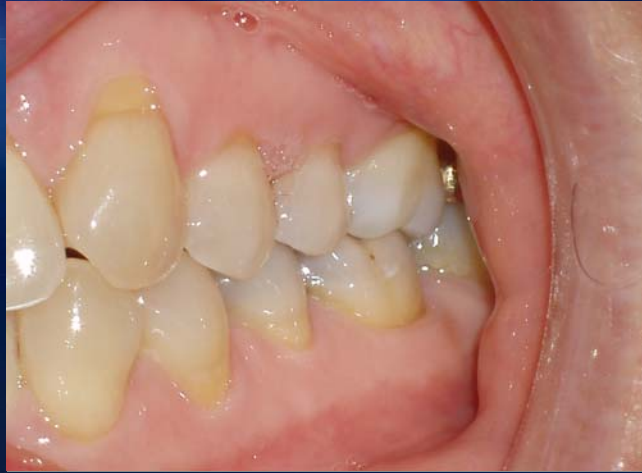Susan - Before



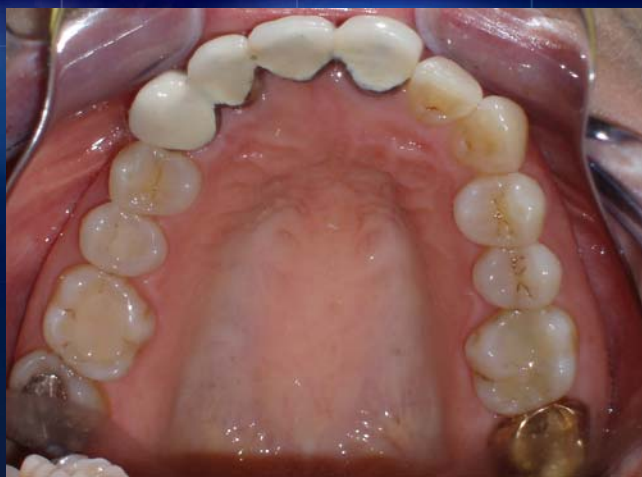Susan - Before



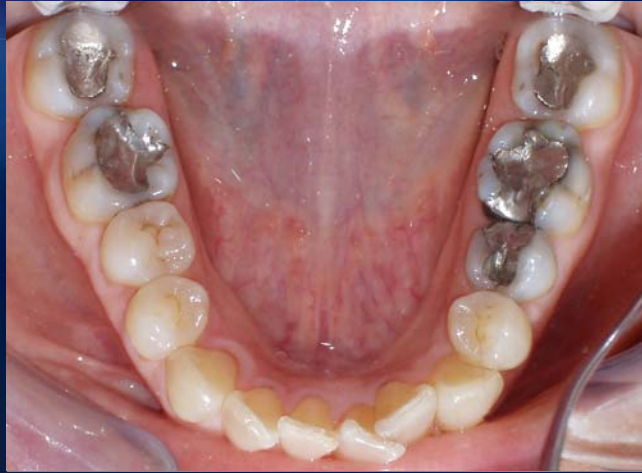Susan - Before



Susan - Before



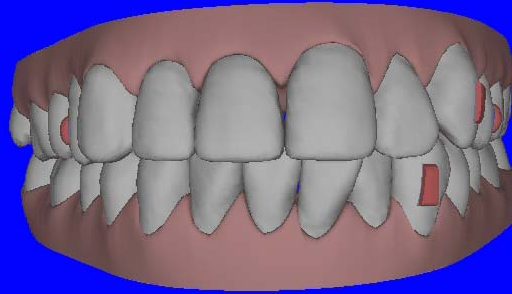
Susan - Before



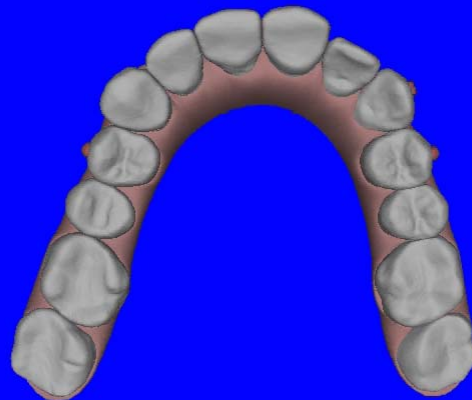
Treatment Form Special Instructions

- “This is a pre-restorative case. The patient has a bridge on teeth #6,#7,#8,#9 tooth #8 is a pontic. Treat teeth #6 and #7 as individual teeth, moving them as needed. Teeth #8 and #9 should be moved as one unit as if connected at the mesial surface, after Invisalign a new bridge will be made on teeth #6, #7, #8, #9. Limit expansion of maxillary teeth to the molars and premolars, do not expand the canines #6, #11. Please bring case to the attention of Dr. Franco.”

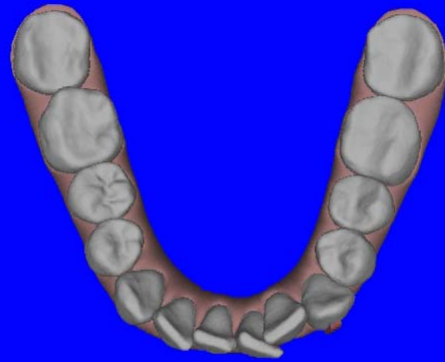Susan - ClinCheck



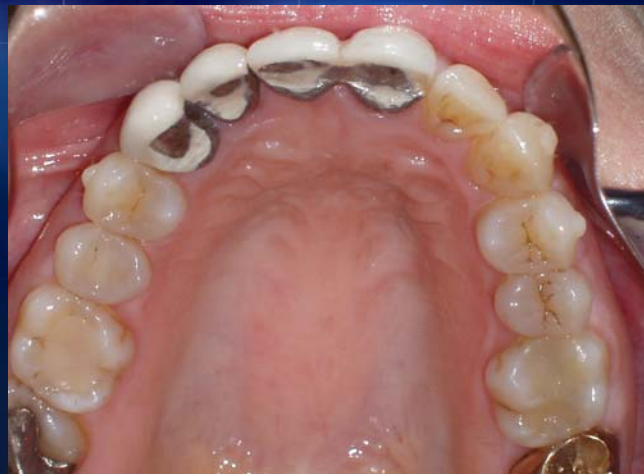Susan - ClinCheck



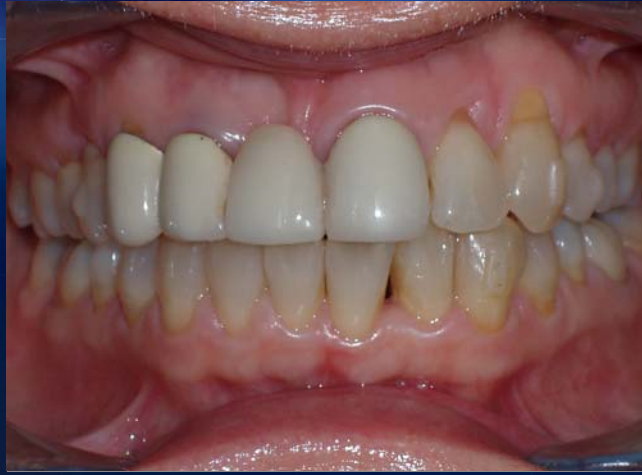Susan - ClinCheck



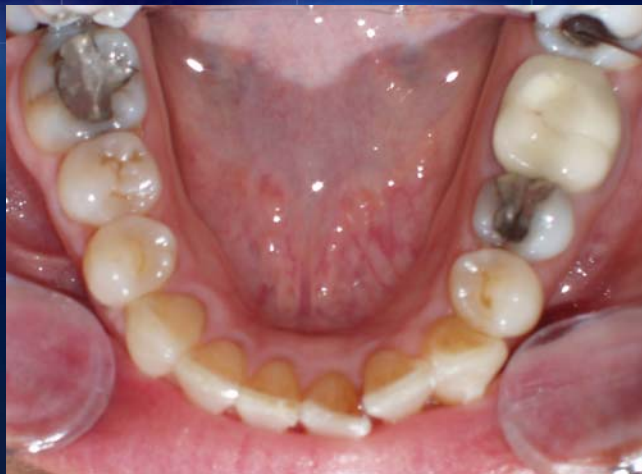Susan - In Progress



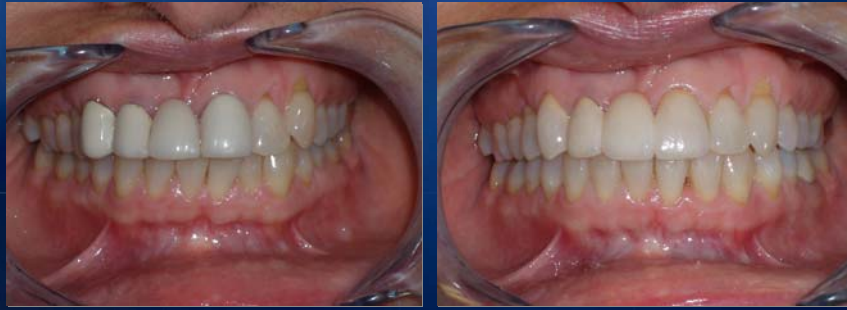Susan - In Progress



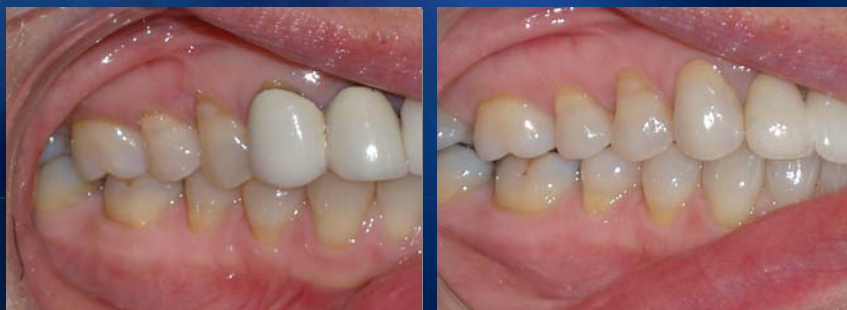Susan - In Progress



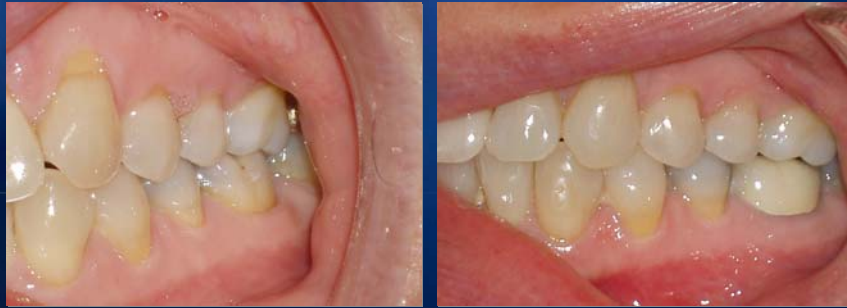Before & After
Prosthetics courtesy of Dr. Gene Goetz



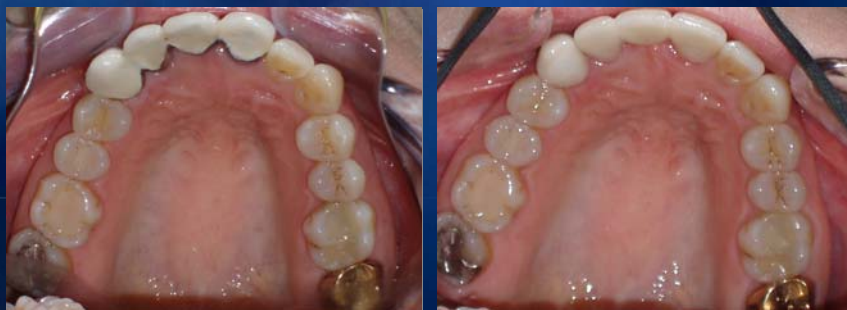Before & After
Prosthetics courtesy of Dr. Gene Goetz



Before & After
Prosthetics courtesy of Dr. Gene Goetz

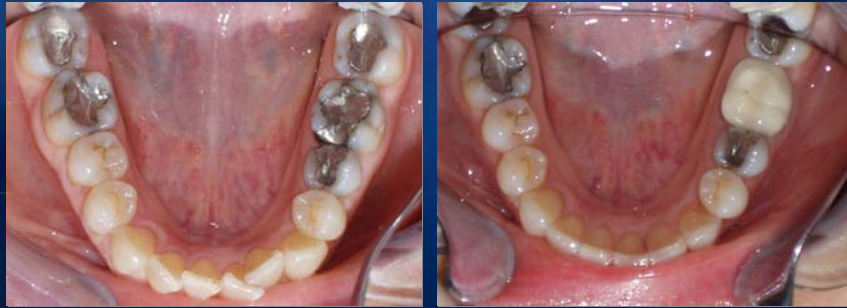

Before & After
Prosthetics courtesy of Dr. Gene Goetz



Before & After

Prosthetics courtesy of Dr. Gene Goetz

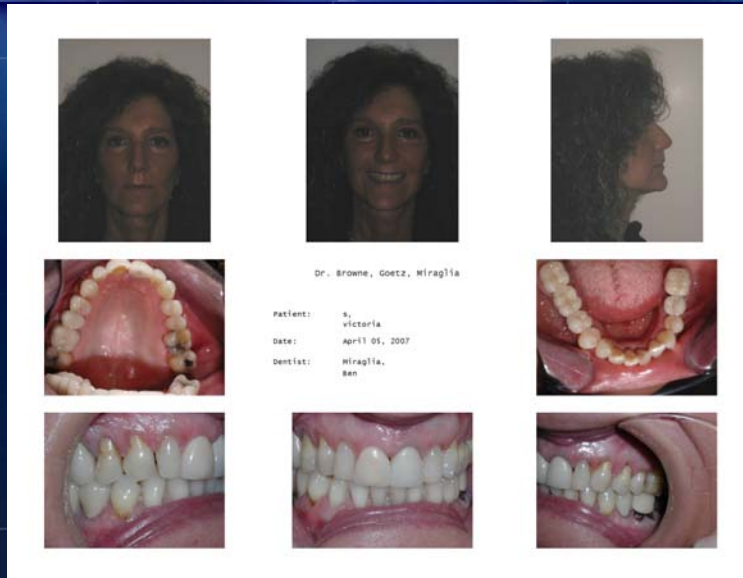

Susan

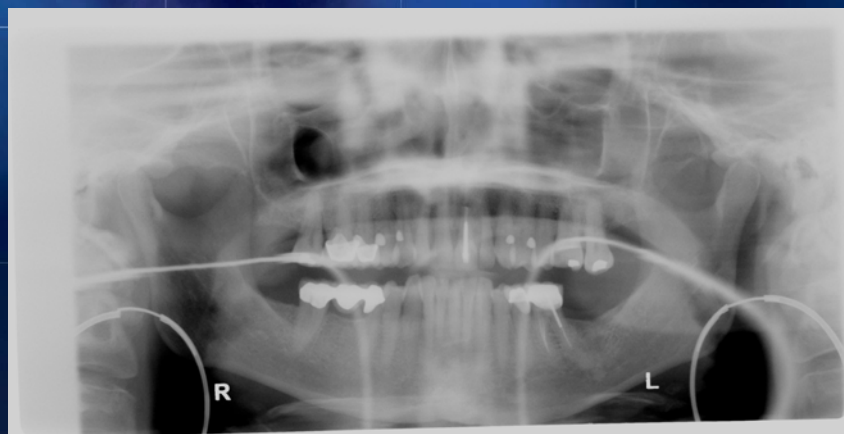Before & After



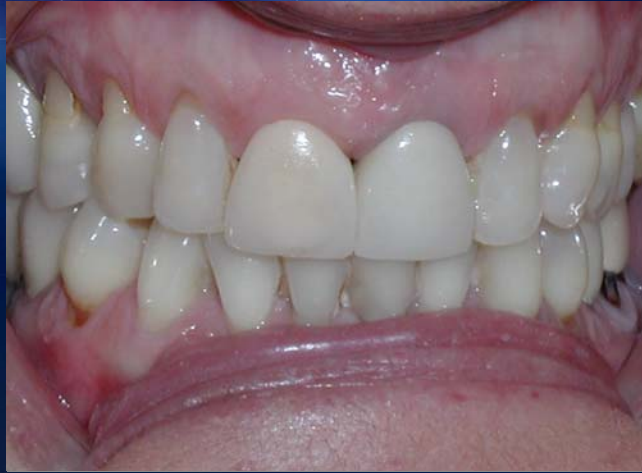Victoria – 58 Years Old 14 Months Treatment Time



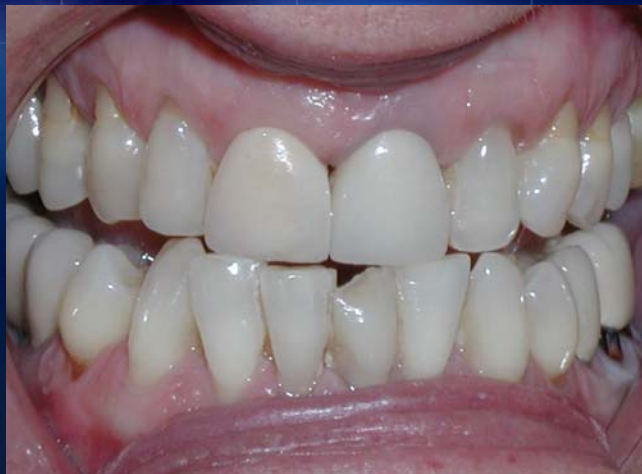Victoria's X-Ray



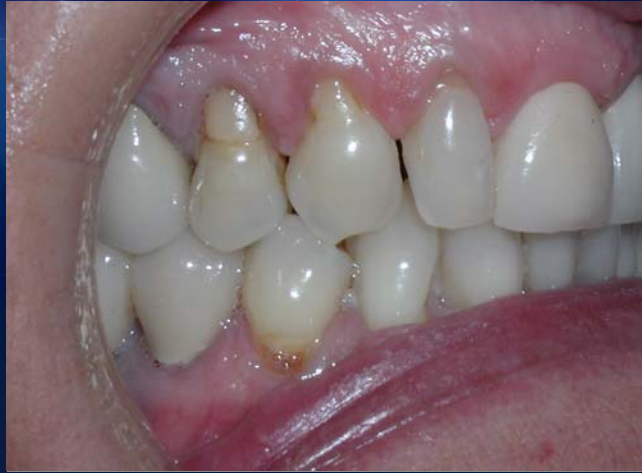Victoria - Before



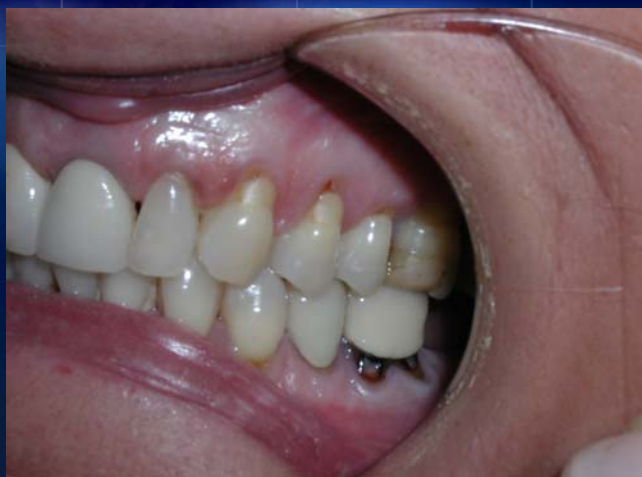Victoria - Before



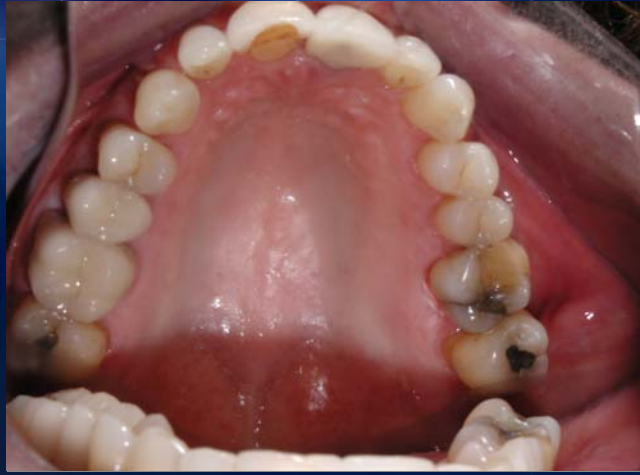Victoria - Before



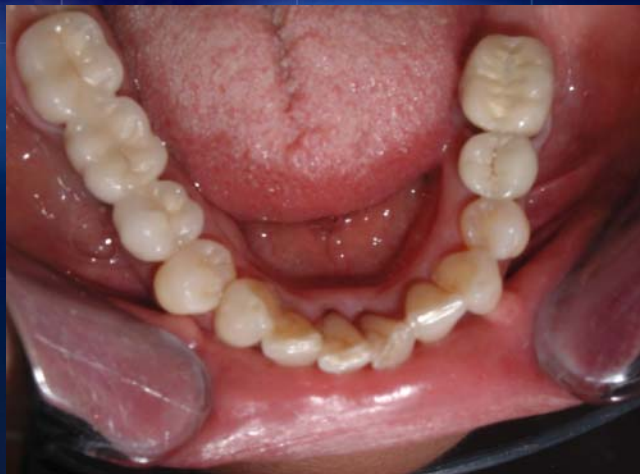Victoria - Before



Victoria - Before



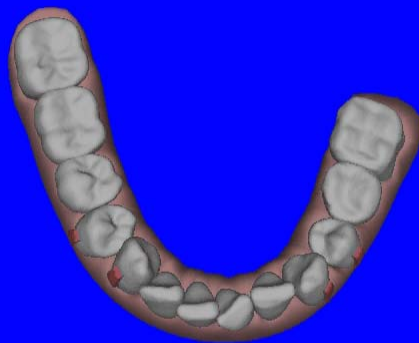Victoria - Before



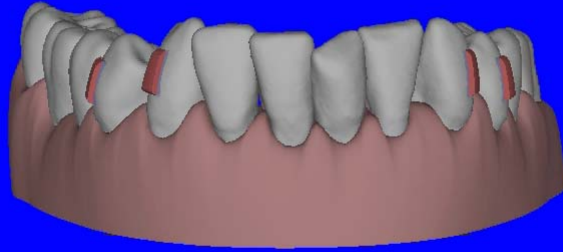
Treatment Form Special Instructions

- “Maxillary arch will be a restorative case. Teeth #3-14 will be full crowns once Invisalign is completed on lowers. It is ok to IPR .5mm from the mesial of tooth #20. Please intrude lower anteriors to level curve of spee and align teeth by rotations with IPR.”

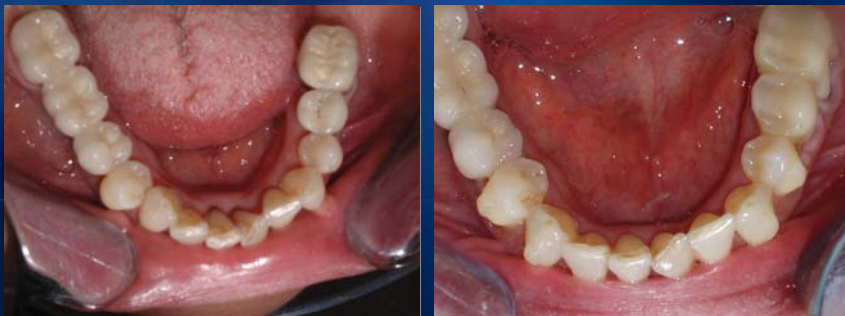Victoria - ClinCheck



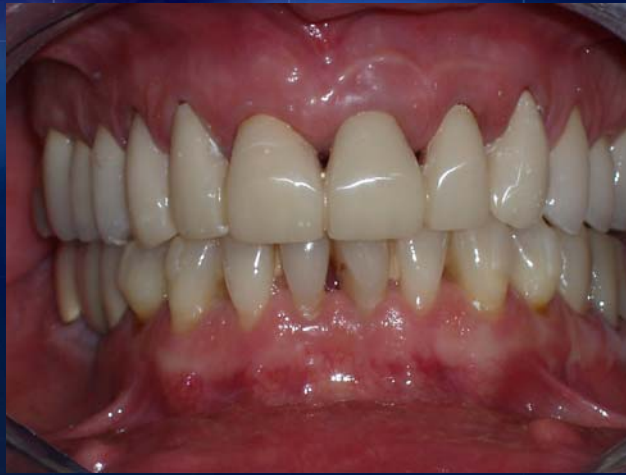Victoria - ClinCheck



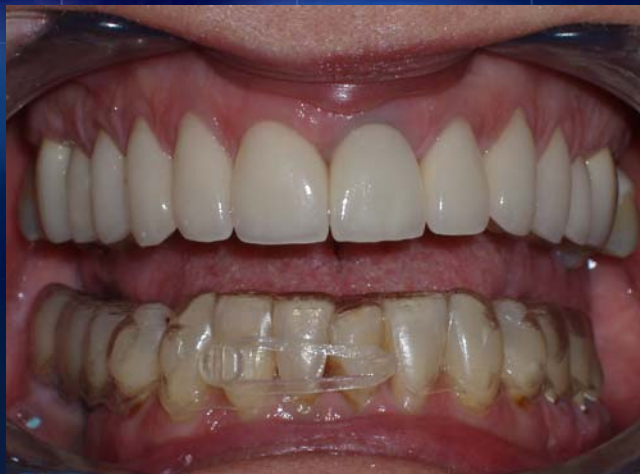Victoria Half Way



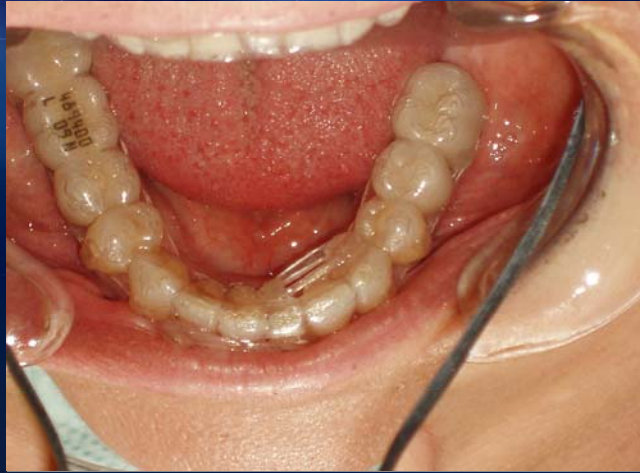Victoria - Temps



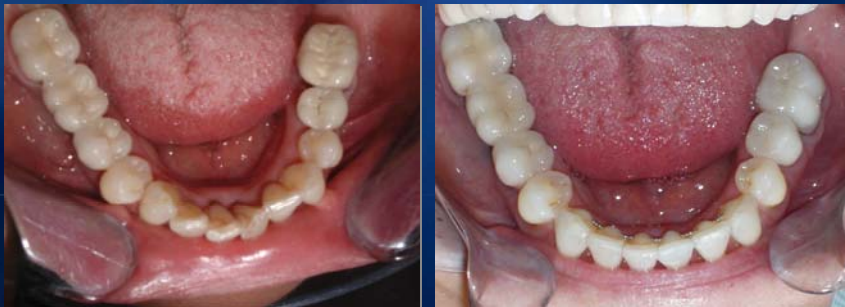Victoria
Rotation with Buttons & Elastics



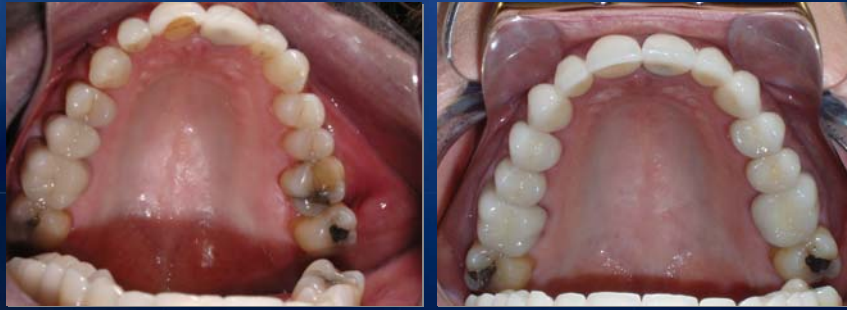Rotation Completed in 8 Weeks



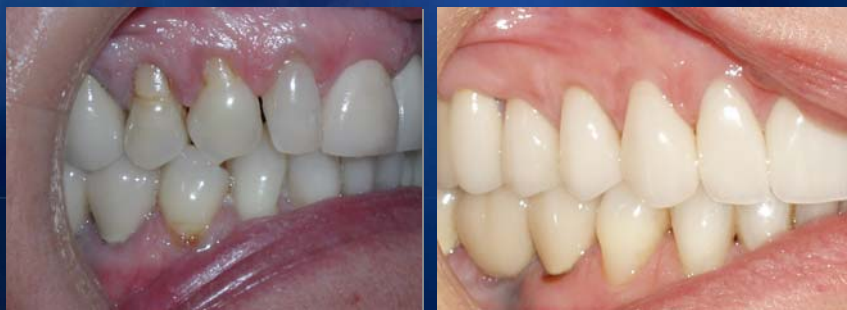Victoria
Before & After



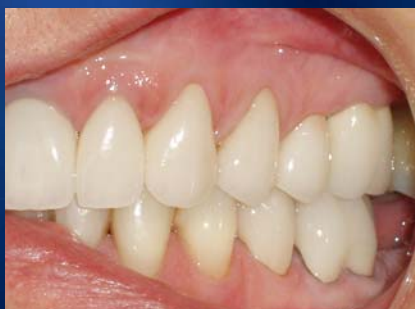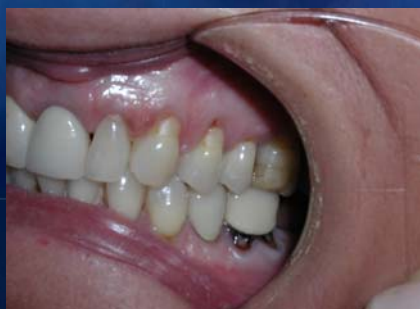Victoria
Before & After



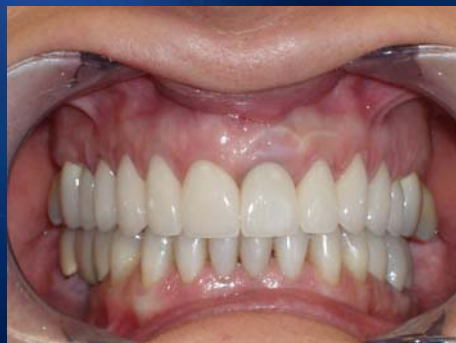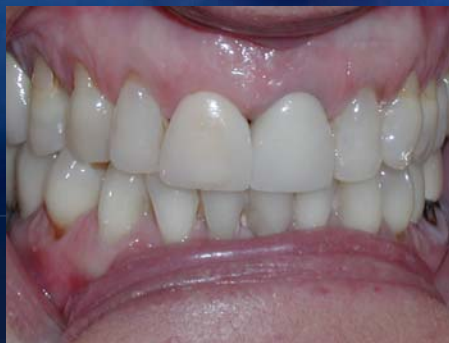Victoria
Before & After



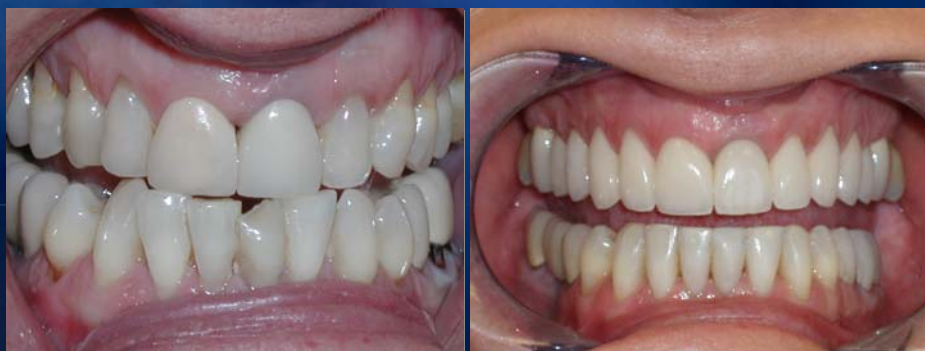Victoria
Before & After



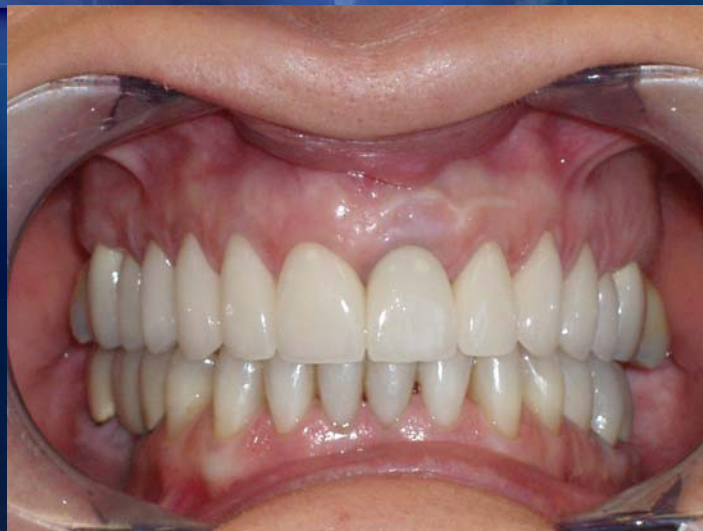Victoria
Before & After



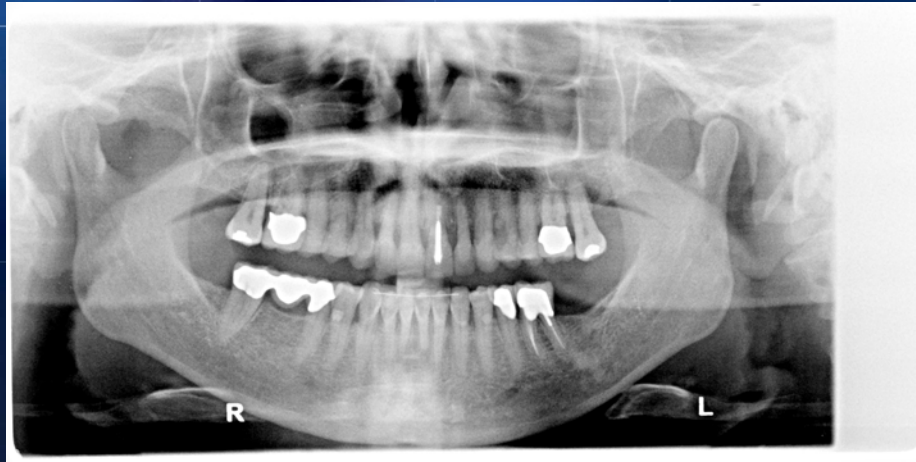Victoria
Before & After



Victoria
14 Months Treatment Time



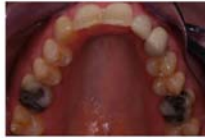Victoria's Final X-Ray



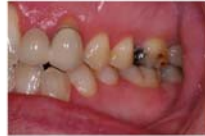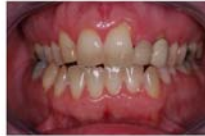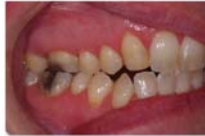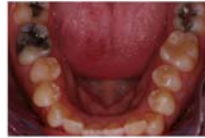Victoria Before & After



Barbara - 52 years old
10 Month Treatment time



Dr. Ben Miraglia
Patient: Barbara,
Before
Date: September 12, 2007
Dentist: Miraglia,
Ben



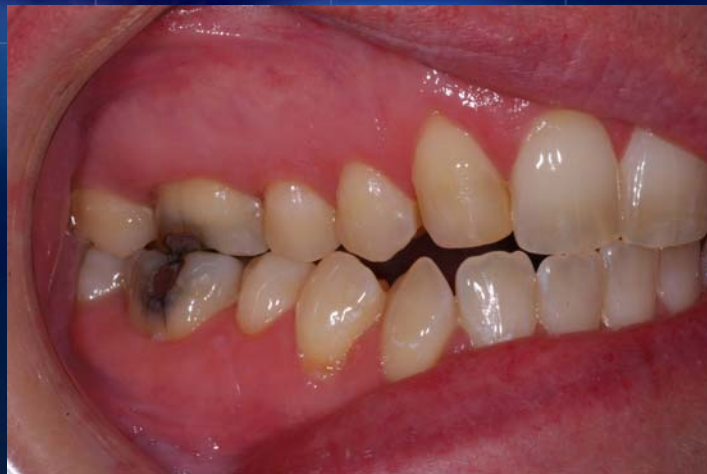Barbara



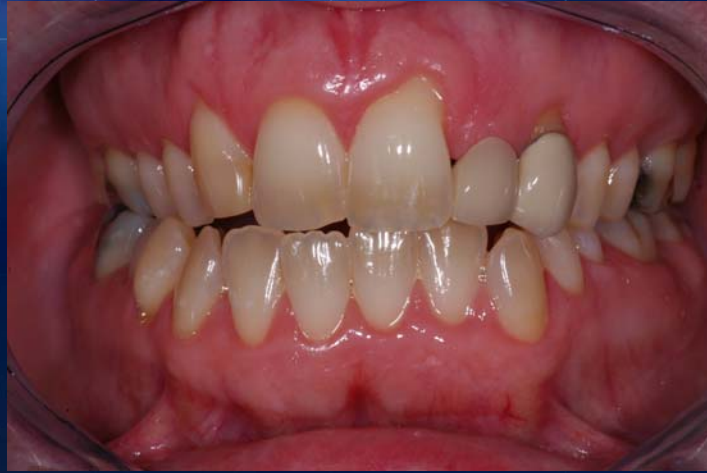Barbara



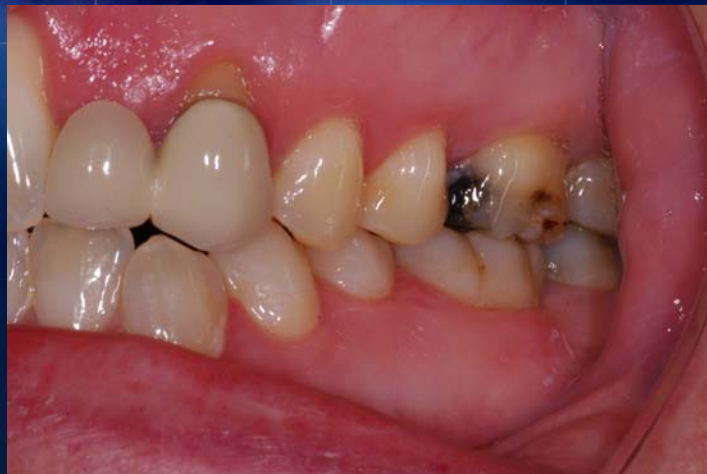Barbara - Before



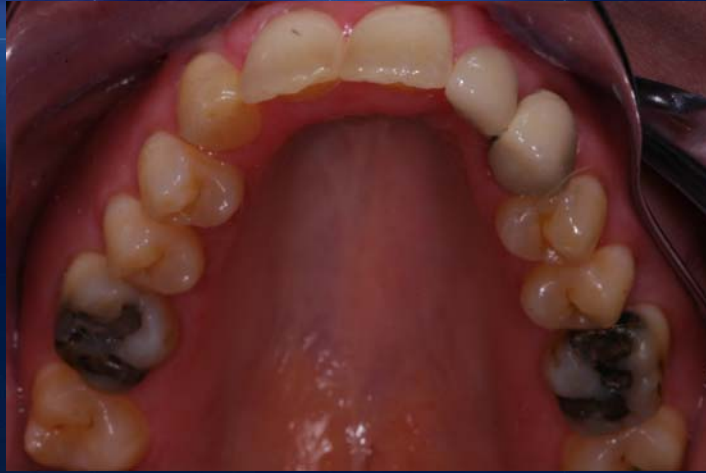Barbara - Before



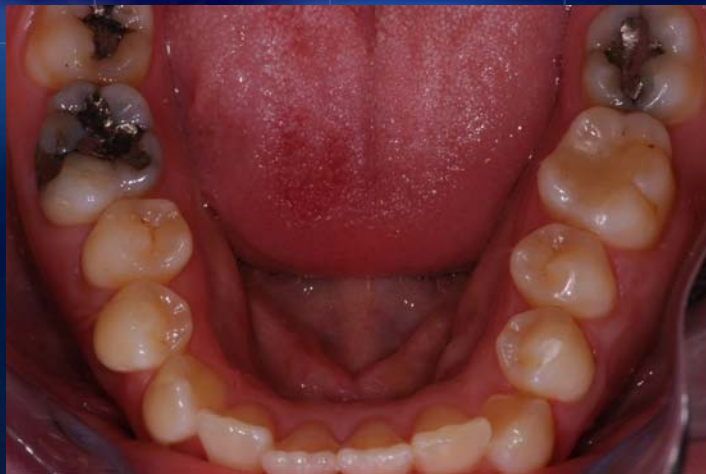Barbara - Before



Barbara - Before



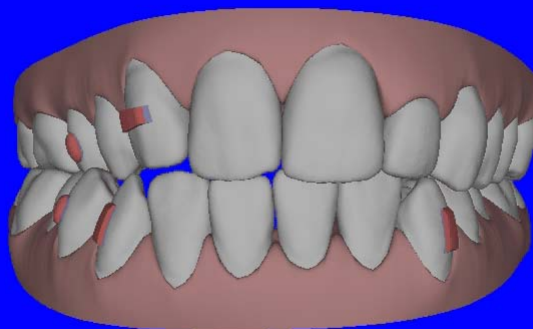
Barbara - Before



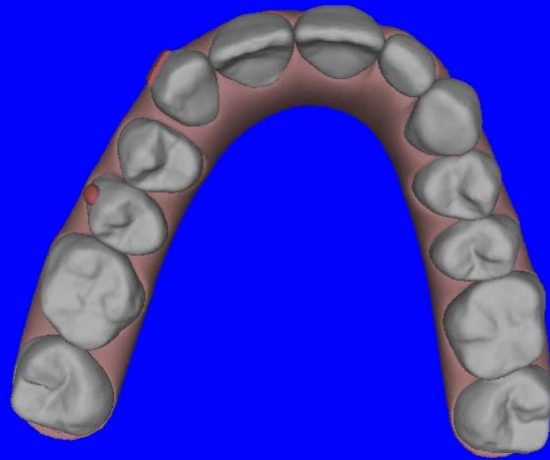
Treatment Form Special Instructions

- Teeth 7 & 10 are missing, Tooth 6 was moved into position of Tooth 7. Teeth 10 & 11 are connected as a two unit splint so they have to move together. Tooth 10 is the pontic. No IPR around tooth 10. Level and align arches. Bring tooth 5 mesially to close space between teeth 5 & 6. Keep space between teeth 4 & 5 if teeth 2, 3 & 4 cannot be moved mesially to close all space. Ok to IPR upper left posterior to move tooth 11 distally for the midline shift.

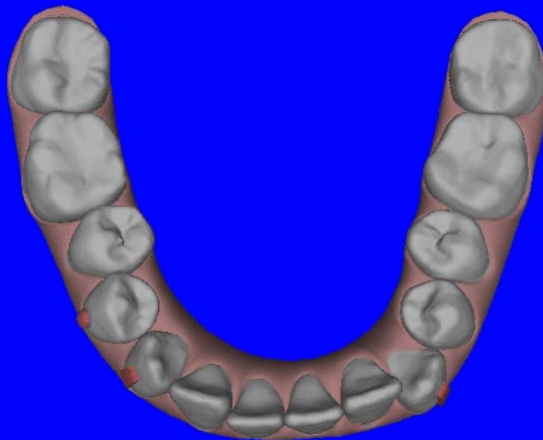Barbara - ClinCheck



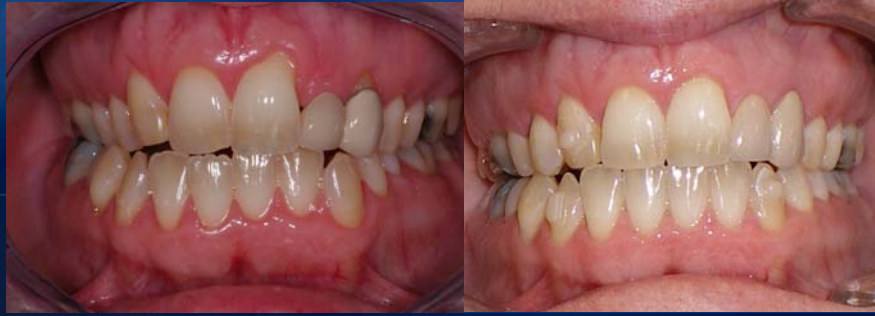Barbara - ClinCheck



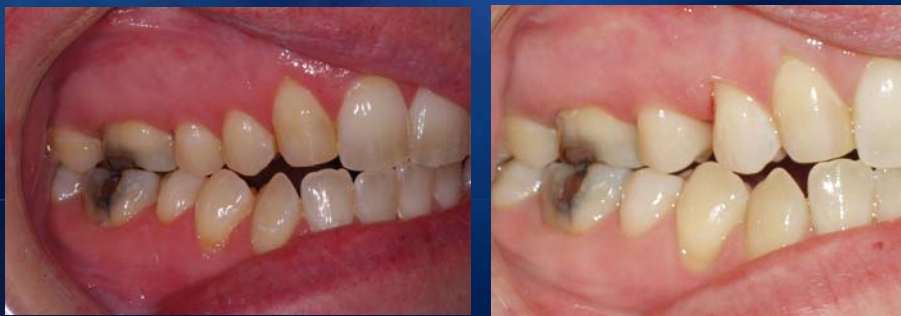Barbara - ClinCheck



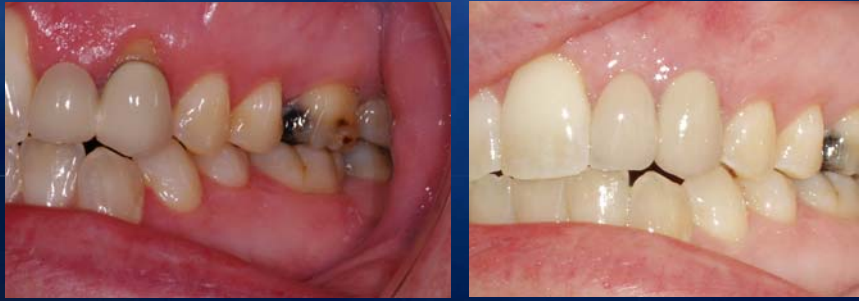Barbara
Before & After



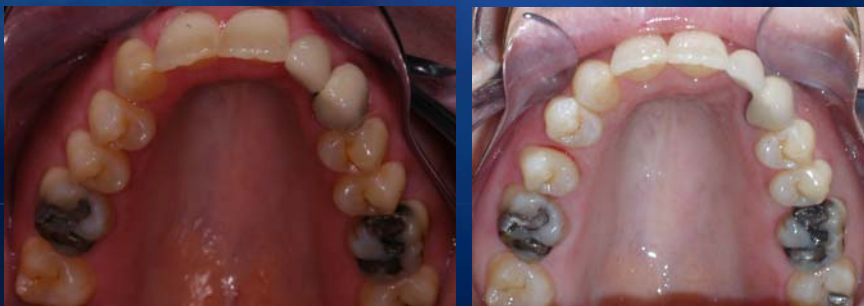Barbara
Before & After



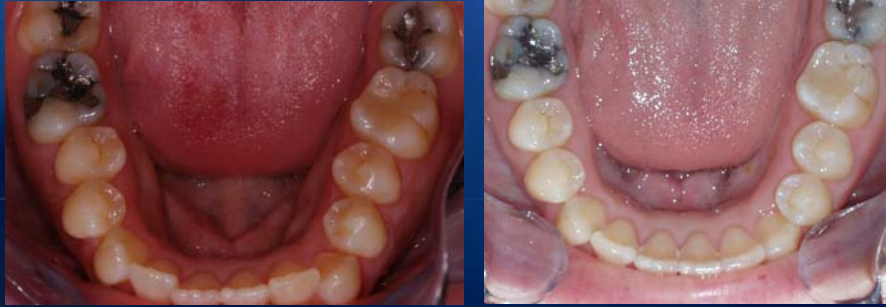Barbara
Before & After



Barbara
Before & After



Barbara
Before & After



Thank
You