



## Techniques for Anterior Open Bite Correction with Invisalign

By Dr. William V. Gierie II, DDS, MS, PA

Anterior open bite is one of the most difficult malocclusions to treat and to retain. The ability to control the posterior vertical dimension is the key to success with open bite treatment. This is why Invisalign is my appliance of choice for open bite patients. With aligners, we can eliminate the bite opening effects of braces and achieve more predictable results.

Here are tips for using Invisalign to close anterior open bite:

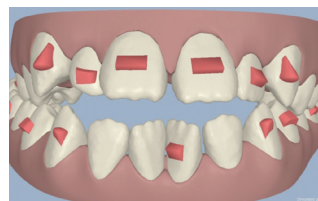
### TIP 1: ANTERIOR OPEN BITE CAN BE CORRECTED BY ANTERIOR EXTRUSION OR POSTERIOR INTRUSION, AND WHICH METHOD TO EMPLOY IS BASED ON THE PATIENT'S INITIAL FACIAL AESTHETICS.

Check the amount of incisor and gingival display at rest and during a dynamic smile. In addition, the smile arc and the relationship of the upper incisors to the lower lip curvature during smile will influence the decision whether to extrude the incisors or to intrude the posterior teeth. For example, for a patient with excessive incisor and gingival display, with a good smile arc, you would want avoid anterior extrusion which will tend to worsen anterior aesthetics.

### TIP 2: IF YOU ARE PLANNING ON ANTERIOR EXTRUSION, SET UP ATTACHMENTS FOR EXTRUSION AND RETENTION.

Optimized attachments are very helpful for extrusion. When multiple optimized attachments are placed on the anterior teeth for extrusion, retention attachments on the molar or premolar can help counteract the posterior unseating of the aligner that may occur.

When multiple optimized attachments are placed on the anterior teeth for extrusion, retention attachments on the molar or premolar can help counteract posterior unseating of the aligner that may occur.

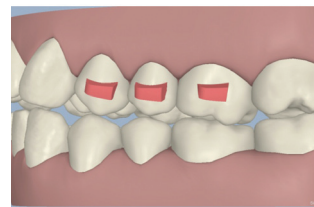


**TROUBLESHOOTING TIP:** In the case that a gap opens between the aligner and an extruding tooth, I first check that the interproximal contacts are not heavy. A tooth will not extrude with heavy interproximal contacts. I would also check that the patient's compliance is in the 20 hour/day zone.

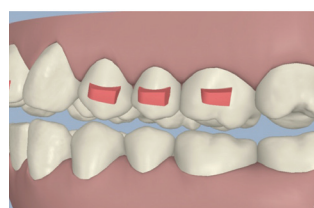
Also, if there is a lag with the extrusion, I use the dimple plier to place a dimple gingival to the optimized attachment bubble in the aligner to augment the retention. Then instruct the patient to use a toothbrush handle to gently bite the aligner into place. I have found that up to 1mm of discrepancy between the aligner and tooth can be recaptured over time using this technique.

### TIP 3: 1 TO 2 MM OF ANTERIOR BITE CLOSURE CAN BE ACHIEVED WITH SEQUENTIAL POSTERIOR INTRUSION USING ALIGNERS.

Sequential posterior intrusion means intruding one posterior tooth at a time, starting with the most distal tooth first. To intrude a posterior tooth, a horizontal beveled attachment is necessary on the one tooth mesial to the tooth being intruded.



UL7 is intruded with an attachment on the UL6 to seat the aligner. The attachment on the UL5 in turn helps to seat the aligner while UL6 is being intruded.



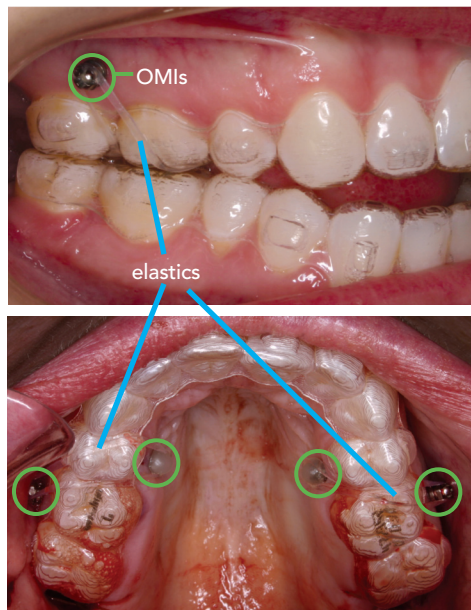
Sequential intrusion of the posterior teeth continues until a posterior open bite is created. The posterior open bite allows the mandible to autorotate and close the bite.

**TIP 4: ORTHODONTIC MINI IMPLANTS (OMIs) CAN BE USED WITH ALIGNERS TO ACHIEVE OPEN BITE CLOSURE OF 3MM OR MORE.**

One advantage of using OMIs with aligners is that the occlusal coverage of the aligners seems to control compensatory eruption of the lower posterior teeth. OMIs, in conjunction with aligners, can intrude posterior teeth to allow autorotation of the mandible and closure of more severe open bite cases.

- **Omi placement:** In order to create the intrusive movement in the posterior, 2 buccal and 2 palatal OMIs are placed as distally as possible in the maxillary—ideally between the U6's and U7's. OMIs are routinely or mandibular buccal for intrusion. OMIs can be placed in the palate, but not on the lingual in the mandible due to the blood vessels and nerves in the vicinity.

In the case of a posterior crossbite, the palatal OMI can be omitted. Instead, hook the elastic directly onto the aligner by creating a notch on the lingual, and this will provide some expansion of the posterior at the same time that the teeth are being intruded.



Note:  
Patient bleeding from  
having wisdom teeth  
removed recently

- **Elastics wear protocol:** I typically start the patient with the intrusive elastics on the second visit to give the patient the chance to get used to the aligners. I typically start with a 1/8, 4.5 oz elastic, which is slinged palatal to buccal over the aligner, as seen in the photograph. Once the teeth start to intrude, I will often go up to a 6 or 6.5 oz elastics.

- **Attachments:** When using OMI's posteriorly, having anterior attachments to assist with extrusion (if this is also needed) or retention is helpful.
- **Setting up the ClinCheck treatment plan for posterior intrusion with OMIs:** Request from your technician posterior intrusion to create an open bite in the posterior. Then use surgical simulation of mandibular auto-rotation to close the bite.

Dr. William Gierie reached the level of Invisalign® Elite Advantage Provider in 2005 and has been treating Invisalign patients at his Wilmington, North Carolina Practice since 2000. Dr. Gierie is also an associate adjunct professor in the department of orthodontics at the University of North Carolina, where he teaches Invisalign and Diode laser use. He has published research on tooth eruption with Dr. William R. Proffit and contributed Invisalign material to the 4th and 5th editions of Contemporary Orthodontics.

**TIP FOR COMMUNICATING WITH TECHNICIANS:**

Provide specific instructions for how you want the treatment setup. For example, intrude tooth X by Xmm or extrude tooth X by Xmm. Do not request protocol by doctor's name, as this will not be understood by your technician.